

Study of Histological changes in the kidney of female white rat treated with Cefixime Drug

Zainab Abdul Kareem Abbas

Department of environmental health, College of Applied Medical Science,
University of Kerbala, Kerbala, Iraq.

zainab.a.abbas@uokerbala.edu.iq

Abstract

This study was prepared to discuss the histological changes caused by Cefixime treatment on female rats. 24 animals were selected with weights about 170-220 grams & These animals were in good health, were subjected For good ventilation and suitable laboratory conditions, the animals were divided into (3) groups. The group (1) Was isolated with Distill Water as a control group & the other groups were given using Cefixime as an overdose for 10 days, and 5 days respectively every 12 hours daily. The results appeared that tissue damage occurred in the kidney tissues as: Renal tubular Dissection, Necrosis of the renal tubules, proliferative glomerulonephritis, hemorrhage within the kidney tissue.

Keyword: Cefixime, kidney tissues, hemorrhage

Introduction.

Antibiotics are constantly freed into the Environment & subsequently enter to human body through various ways. At same time, excessive used of its can also lead to a series of negative consequences (Miao, et al,2024).

Overuse of medicines in general is regarded one of the largest health Social & economic troubles in different parts of the world (Tadele & Kalkidan,2014).

The use of one or more herbal or synthetic Drugs without a doctor's Diagnostic as well as non-prescription or therapeutic observe leads to an excess in factors such as Bacterial Resistance, absence of optimal Treatment, Even Poisoning & other negative side effects (Mehuys et al,2014).

Cefixime is an oral third generation cephalosporin antibiotic with in vitro Bactericidal activity against a broad types of (G +ve) & (G -ve) organisms, It is indicated for the treatment of 'Acute Infections' like 'Upper Respiratory Tract Infections (URTI), Lower Respiratory Tract Infection'(LRTI) & Specially in Urinary Tract Infections' (UTI) (Al Haboob,2018). This drug not be used during pregnancy or breast-feeding unless Considered essential by the doctor (Mohseni. et al ,2018).

Material & Method

Experimental animal:

Twenty adult rats weighing 170-220 g Were brought from the Animal House at university of Karbala, College of Pharmacy. They were transferred to a room with suitable temperature and humidity. The female rats were placed in plastic cages measuring 30 x 50 cm. A suitable amount of food and water was placed in the cage every day to complete the experiment. The sawdust was changed approximately every week. The rats were placed in the animal house for several days to adapt before starting the experiment (Leng *et al*, 2020).

Experimental design:

The experiment involved the used Female 'Sprague Dawley rats' (S.D.R.) which ten-week- old & weighing 170-220 grams in cages in the animal house and fed a commercial diet and water. The experiments involved 24 (S.D.R.) at random divided into 3 groups (n = 8). The Animals in G (2) was Treated with drug for (10) days. While The Animals in G (3) was Treated with drug for (5) days, but Animals in G (1) were used as a control group. Cefixime was supplied by "Samaraa Drug Industry, Iraq", was capsule given every 12 hours. Cefixime overdoses of 120 mg/kg body weight were given to animals orally, and the treatment dose was determined based on the dose given to humans (Nair & Jacob (2016).

Histopathological

Kidney tissue samples were fixed in 10% formalin for 24 hours , before being dehydrated with ethyl alcohol at increasing concentrations of 70%, 80%, 95%, 100% and 100%. Samples were cleared with xylene and then embedded in paraffin which were sectioned at 5 µm and stained with hematoxylin and eosin. These samples were examined under a light microscope at 400X magnification. (Anthony,2016).

Results

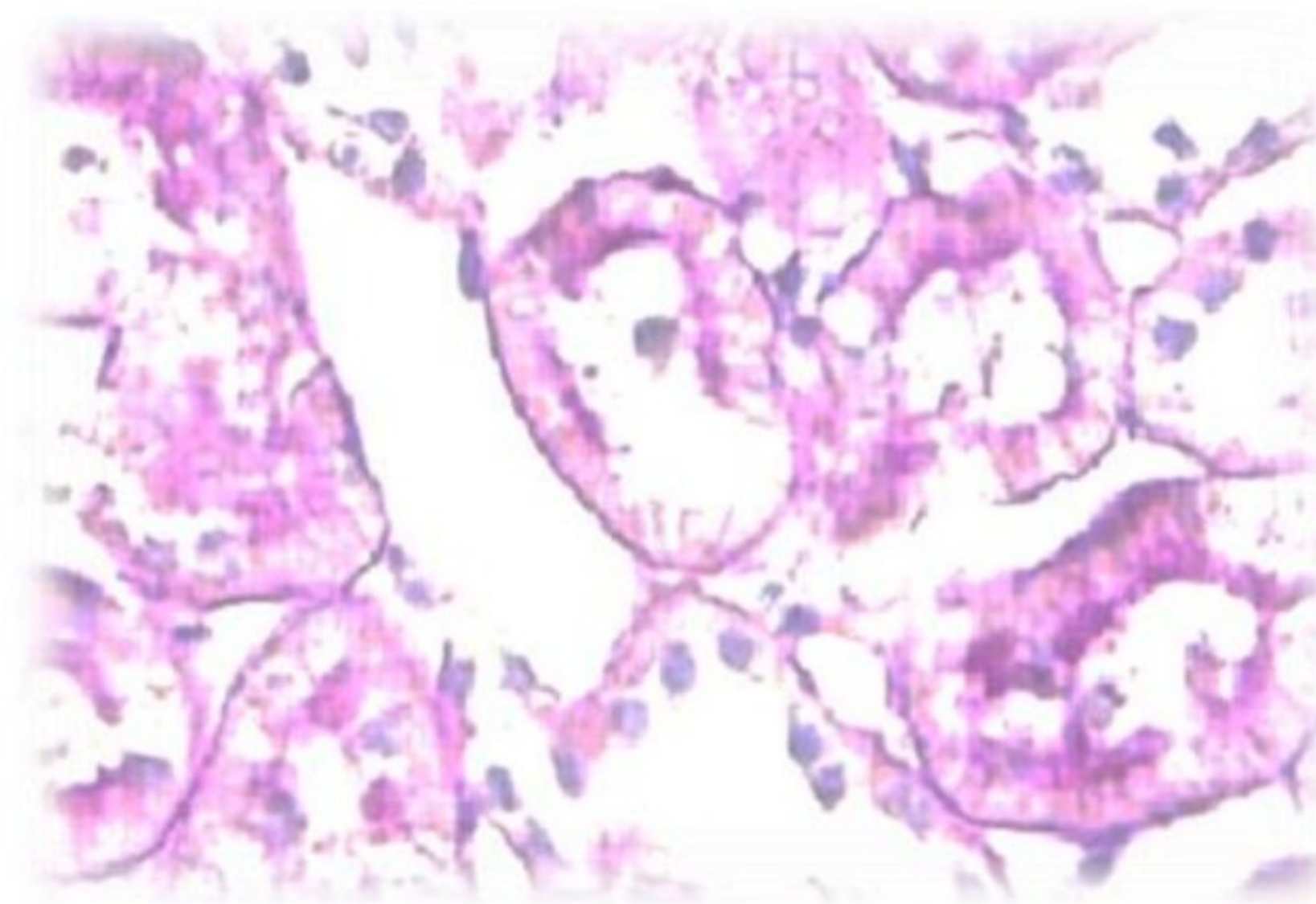


Figure 1: Cross Section of the kidney of a female rat (control group), showing: Renal tubules.: (Stained (H & E, 400X).

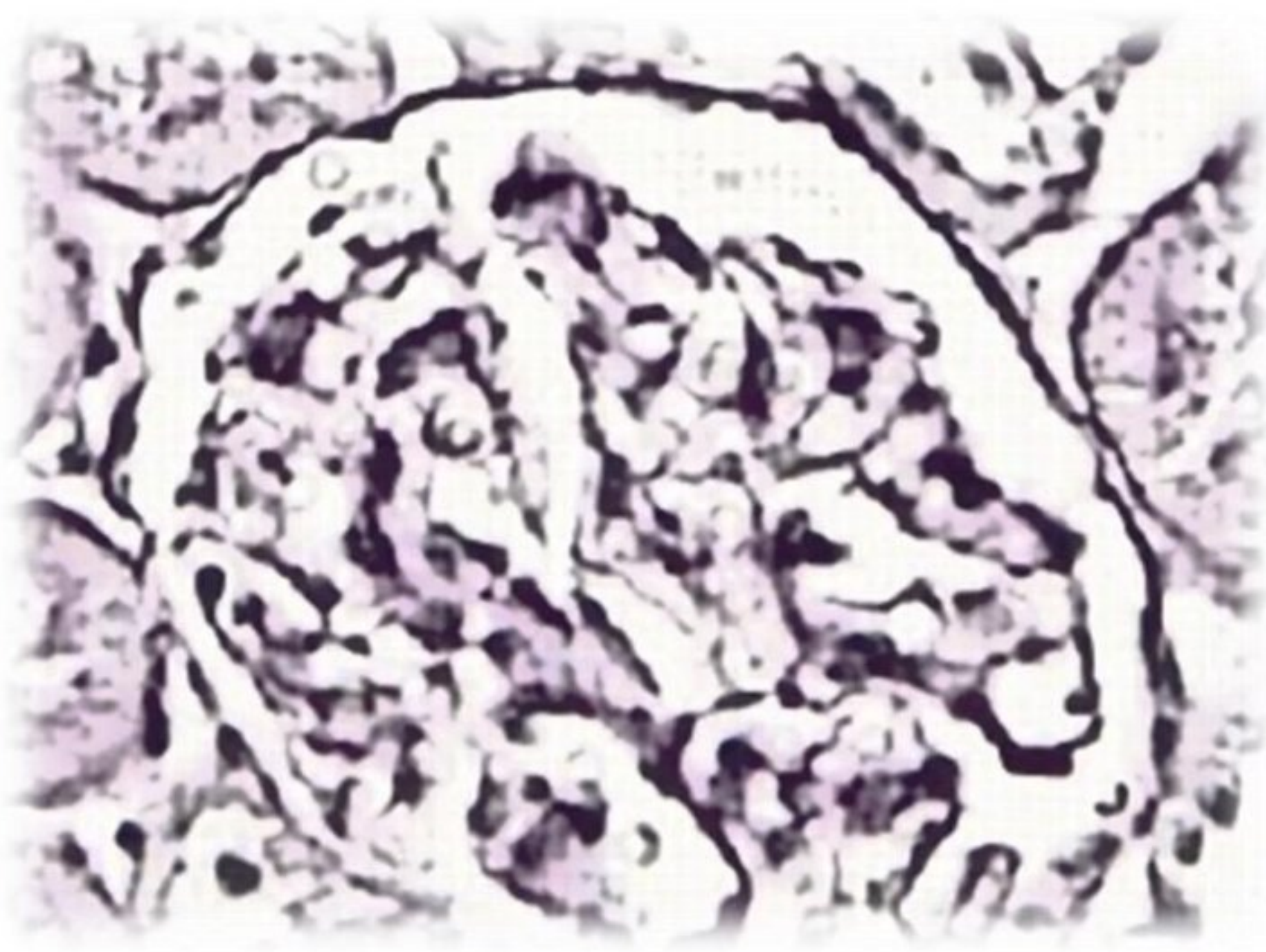


Figure 2: Cross Section of the kidney of a female rat (control group), showing : Renal glomerulus (Stained (H & E, 400X).

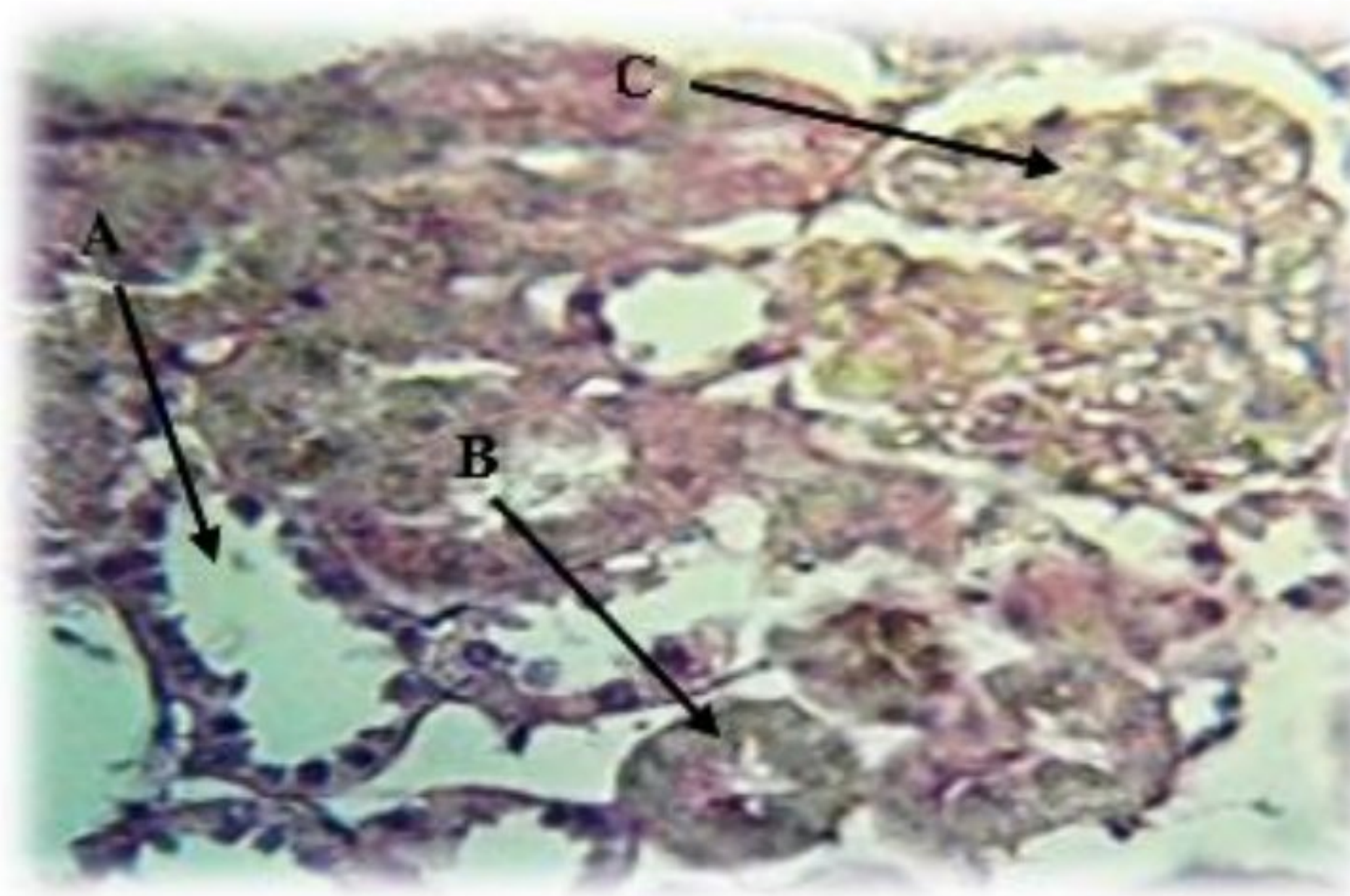


Figure 3: Cross section of the kidney of a female rat treated with the drug for 10 days, showing (A) Renal tubular Dissection: (B) Necrosis of the renal tubules (C) proliferative glomerulonephritis (Stained (H & E), 400X).

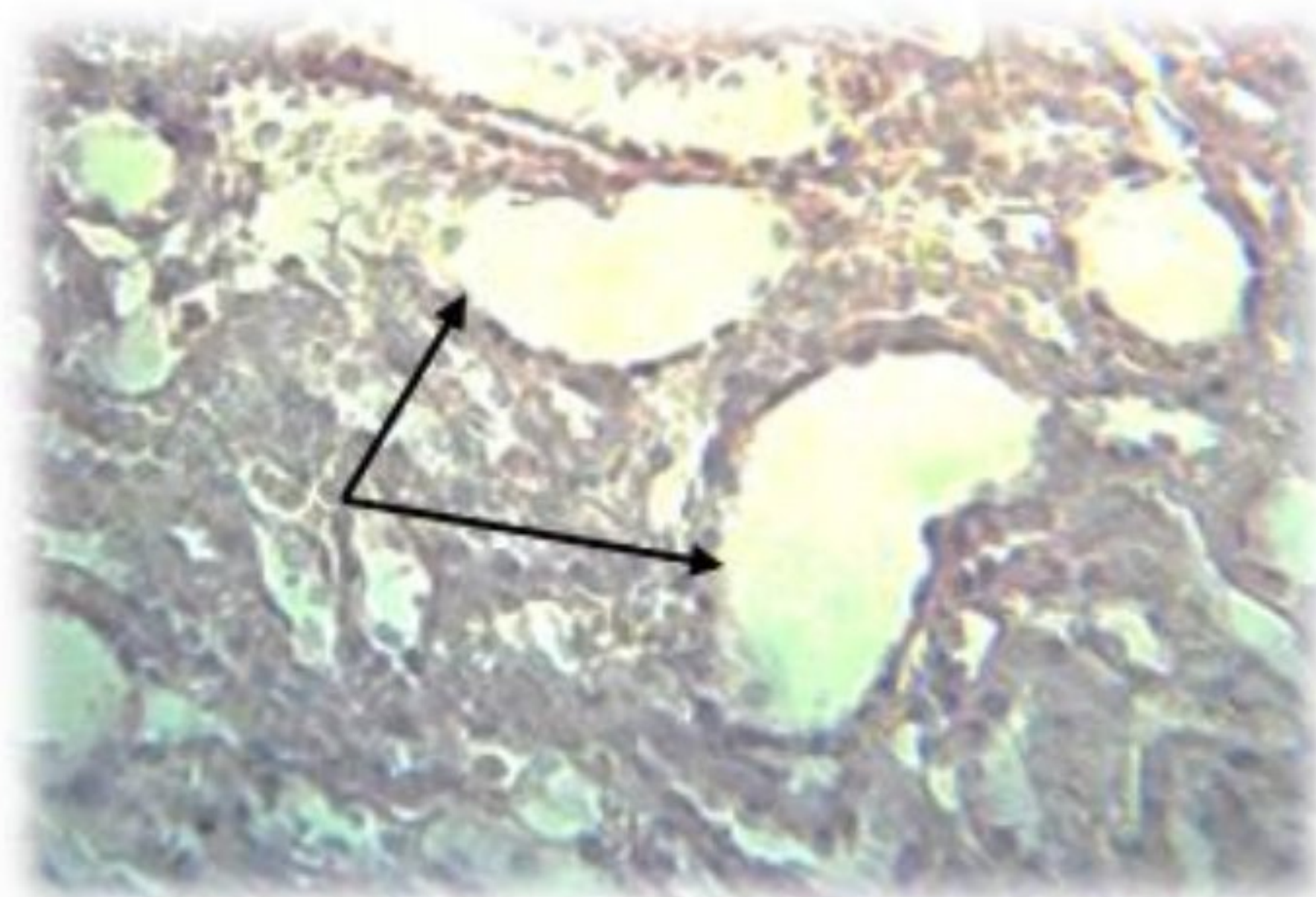


Figure 4: Cross section of the kidney of a female rat treated with Cefixime for 10 days showing: Enlargement Henle's Loop. (Stained (H & E), 400X).

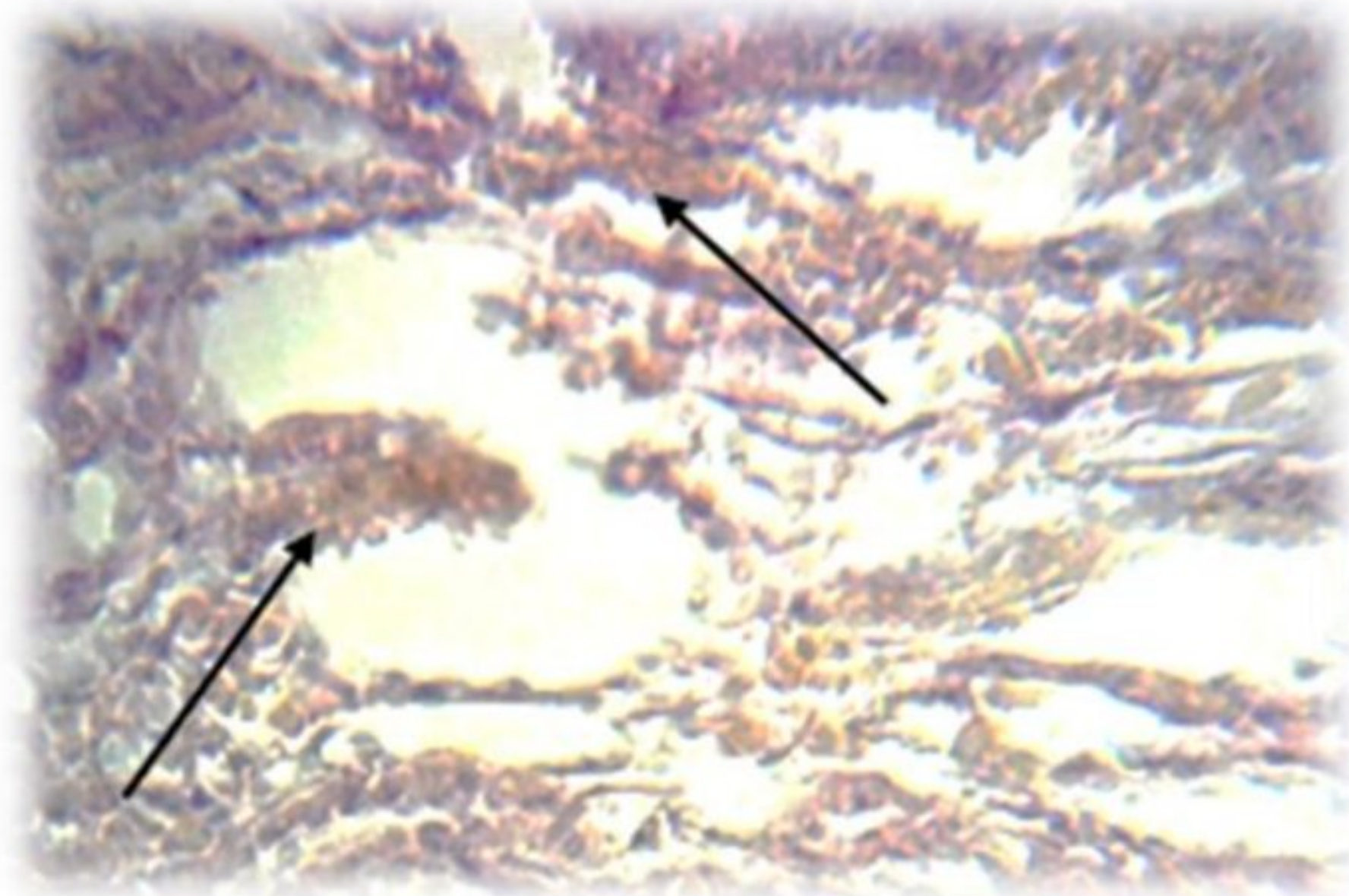


Figure 5: Cross section of the kidney of a female rat treated with Cefixime for 10 days showing: hemorrhage (Stained (H & E), 400X).




Figure 6: Cross section of the kidney of a female rat treated with Cefixime for 5 days shows (A&B) hemorrhage within the kidney tissue : (C) Renal tubular Dissection . (Stained (H & E), 400X).

Discussion

Treatment with cephalosporins, including cefixime, causes renal tubular necrosis. High doses of cephalosporins can lead to kidney toxicity (Azzam,*et al*,2024).which includes impaired kidney function due to mitochondrial damage, especially in animal studies. Cefixime Drug is Most used to treat infections in children, and can also commonly cause "acute kidney failure" which is among the many reported side effects of cefixime and other cephalosporins. (Al Haboob,2018).

In this study the results of histopathological examination of kidney tissue sections in animals treated with the drug showed clear histopathological changes in the cortex and medulla

Conclusion

The present study concluded that Over doses of Cefixime treatment had negative & histological effect on the kidney tissue. It is not recommended for use in patients with kidney disorders.

References

- [1] Al Haboob, A. A. N. (2018). Cefixime-induced hepatotoxicity and acute renal failure: a case report. *European Journal of Medical Case Reports*, 2(2), 55-58.
- [2] Mohseni, M., Azami-Aghdash, S., Sheyklo, S. G., Moosavi, A., Nakhaee, M., Pournaghi-Azar, F., & Rezapour, A. (2018). Prevalence and reasons of self-medication in pregnant women: a systematic review and meta-analysis. *International journal of community based nursing and midwifery*, 6(4), 272.

- [3] Tadele Eticha, T. E., & Kalkidan Mesfin, K. M. (2014). Self-medication practices in Mekelle, Ethiopia.
- [4] Mehuys, E., Gevaert, P., Brusselle, G., Van Hees, T., Adriaens, E., Christiaens, T & Boussery, K. (2014). Self-medication in persistent rhinitis: overuse of decongestants in half of the patients. *The Journal of Allergy and Clinical Immunology: In Practice*, 2(3), 313-319.
- [5] Miao, S., Yin, J., Liu, S., Zhu, Q., Liao, C., & Jiang, G. (2024). Maternal–Fetal Exposure to Antibiotics: Levels, Mother-to-Child Transmission, and Potential Health Risks. *Environmental Science & Technology*, 58(19), 8117-8134.
- [6] Leng Q, Li Y, Pang X et al. (2020): Curcumin nanoparticles incorporated in PVA/collagen composite films promote wound healing. *Drug delivery*, 27(1): 1676–1685.
- [7] Nair AB, Jacob S.(2016). A simple practice guide for dose conversion between animals and human. *J Basic Clin Pharma* ;7:27-31.
- [8] Anthony, L.M.(2016). Basic histology , Text and Atlas ,fourteenth edition . Indian Univer, School of Med . p-1-4.
- [9] Shaker, S. H., Razooqi, Q. A., & Shaban, R. K. (2020). Negative effect of therapeutic, double and overdoses of cefixime on the liver and kidneys of male albino rats. *Ann Trop Med Public Health*, 23.
- [10] Ahmed TS.(2015). Hepato-renal effects of cefotaxime in albino rats. *Int J Pharm Pharm Sci*;7:312-5.
- [11] Azzam, S. M., Elsanhory, H. M., Abd El-Slam, A. H., Diab, M. S., Ibrahim, H. M., Yousef, A. M., & Zaghoul, M. S. (2024). Protective effects of Pelargonium graveolens (geranium) oil against cefotaxime-induced hepato-renal toxicity in rats. *Frontiers in Toxicology*, 6, 1489310.